

ZEISS CLARUS 500 AND 700

Introduces broad line fundus imaging for fundus autofluorescence



Seeing beyond

What is Fundus Autofluorescence?

Fundus autofluorescence (FAF) is a diagnostic imaging technique used to detect the presence of naturally occurring molecules predominantly in the retina that absorb and emit light of specified wavelengths, known as ocular fluorophores. ZEISS CLARUS 500 and 700 can capture a broader range of autofluorescence generated at the fundus because it illuminates/excites at two wavelength ranges.

Visually, FAF images are represented by a 256 grey-scale value. Low pixel values represent hypo-fluorescent intensities and appear dark, whereas high pixel values represent hyperfluorescent intensities and appear bright. The FAF signal is proportional to the concentration of fluorophores detected.

In clinical practice, FAF is often used to visualize lipofuscin fluorescence in the retinal pigment epithelium (RPE), which is an indicator of RPE health. Healthy RPE appears as a uniform grey color on FAF images. In general, hyper-autofluorescence indicates RPE damage, and hypo-autofluorescence indicates dead or absent RPE. Studies have indicated that FAF images show early RPE disruption in macular degeneration, and predict progression of geographic atrophy^{1,2}. FAF is also indicated in retinal dystrophies, as well as toxic retinopathies such as those caused by hydroxychloroquine use.

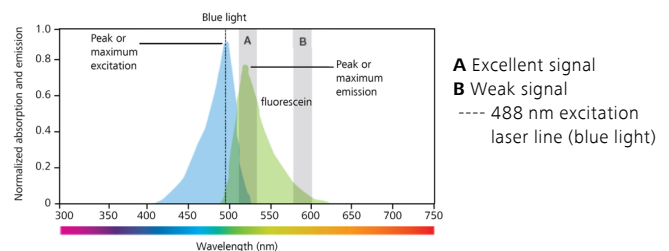
Fluorophores in the Eye

Located in the RPE, lipofuscin is a dominant macular fluorophore that absorbs blue light with a peak excitation wavelength of 470 nm and emits yellow-green light at a peak wavelength of 600–610 nm. However, there are other fluorophores located outside the RPE such as the cornea (with a peak excitation wavelength at 365–480 nm and peak emission wavelength at 620 nm³) and the lens (with a peak excitation wavelength at 420–430 nm and peak emission wavelength at 520 nm⁴). In addition, at an excitation wavelength of 446 nm, collagens in the optic nerve have a peak emission wavelength at 500 nm^{5,6}.

Fluorophore	Peak Excitation (nm)	Peak Emission (nm)
lipofuscin	470	600-610
cornea	365-480	620
lens	420-430	520
optic nerve	~446	500

Fluorescence Fundamentals

To understand the importance of peak excitation and peak emission wavelengths, see the spectral profiles of fluorescein below as an example. Intravenous fluorescein is used in fluorescein angiography. This fluorophore absorbs light from 400 to 530 nm with a peak excitation wavelength of 490 nm. Illumination near the peak excitation wavelength produces the brightest emission. This fluorophore emits fluorescence from 475 to 650 nm, with a peak emission at 525 nm. If the detector only detects light at channel A, fluorescein will have an intense fluorescence signal; however, if the detector detects light at channel B, it will have a dim fluorescence signal. Consequently, the detector wavelength range plays a crucial role in the observed fluorescence.



What does ZEISS CLARUS detect?

Detection is dependent on many factors: the fluorophore peak excitation wavelength, the fluorophore peak emission wavelength, illumination wavelength(s), and the detector range. ZEISS CLARUS illuminates in two wavelength ranges, FAF-Blue (430–480 nm) and FAF-Green (480–570 nm). All fluorophores that absorb light within those ranges will be detected if the fluorophores emit light within the long pass filter range, which is 532 nm for FAF-Blue and 630 nm for FAF-Green. Consequently, the ZEISS CLARUS image may look different from an image obtained by cSLO, which merely detects light emitted from a smaller range of fluorophores.

Capture Mode	Excitation (nm)	Detection (nm)
FAF-Blue	430-480	>532
FAF-Green	480-570	>630

What does cSLO detect?

cSLO utilizes confocal optics in the form of a spatial pinhole that detects light from an optical plane and eliminates out-of-focus light^{7,8}. The confocal design has a limited focal depth that

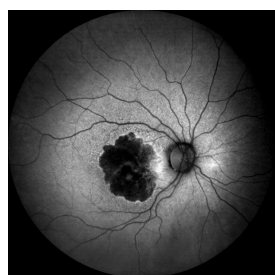
excludes fluorescence from the crystalline lens and interference from other structures outside the focal plane, such as the optic nerve head. This technique illuminates at a single wavelength, which will only excite fluorophores that absorb light with a peak excitation near that wavelength.

Differences between ZEISS CLARUS and cSLO

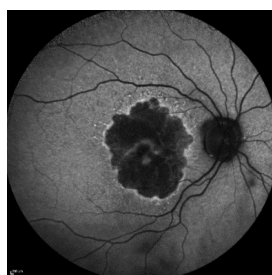
The use of different optical designs and excitation wavelengths between ZEISS CLARUS and cSLO impacts the fluorescence observed. The primary contributing difference in FAF images is the limited focal depth of cSLO, which excludes the fluorescence signal originating outside the confocal plane. ZEISS CLARUS 500 and 700 uses a non-confocal technique called Broad Line Fundus Imaging (BLFI) which has a longer depth of focus than cSLO imaging⁹. With CLARUS, the fluorescence of the optic disc is captured when using FAF-Blue illumination because the collagens in the optic disc absorb light at an excitation wavelength (446 nm) within the excitation range of this capture mode and emits fluorescence within the detection range. cSLO captures minimal fluorescence from the optic disc due to the limited focal depth. It should be noted that although some differences exist between the two systems, the overall pattern of fluorescence due to lipofuscin is similar between ZEISS CLARUS and a cSLO system. Both remain clinically useful in assessing and detecting abnormalities in RPE metabolism.

ZEISS CLARUS Case Studies

The FAF-Blue images below were captured on the same patient using the ZEISS CLARUS 500 and a commercially available cSLO system. The ZEISS CLARUS image clearly shows fluorescence in the optic nerve while the cSLO system image does not. While the nerve appears different, both systems delineate the same geographic atrophy in the macula.

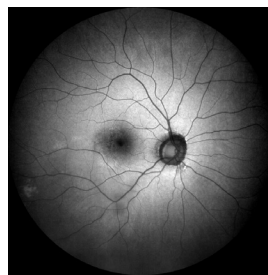


ZEISS CLARUS 500
cSLO FAF-Blue Image

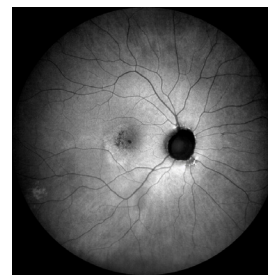


ZEISS CLARUS 500
FAF-Blue Image

Since both FAF-Blue and FAF-Green are capable of exciting lipofuscin within the RPE, both scan types can be used in clinical practice to evaluate retinal disease and will produce similar images in terms of overall patterns of fluorescence (see images below).



ZEISS CLARUS 500
FAF-Blue Image



ZEISS CLARUS 500
FAF-Green Image

Luteal pigments normally found in the macular region absorb blue light, which results in a characteristic reduction of the FAF-Blue signal in that region. As such, the macular region on FAF-Blue images appears hypofluorescent. This effect is not seen on FAF-Green images, since luteal pigments do not absorb green light. Therefore, small abnormalities in the macular region may be more easily seen on FAF-Green. In addition, nuclear cataracts fluoresce under blue light, which will degrade the FAF-Blue image. Therefore, in patients with cataracts, FAF-Green may produce an image with better contrast. The luteal pigment and nuclear cataract effects are due to the blue excitation wavelength and can be observed with both cSLO and ZEISS CLARUS instruments.

Conclusion

ZEISS CLARUS utilizes a non-confocal technique called BLFI for FAF images with the option to choose between green or blue illumination. Consequently, the images acquired by ZEISS CLARUS may look different when compared to a cSLO device that excites at only one wavelength and has a narrow depth of focus. These differences explain why the optic disc is bright in a ZEISS CLARUS image and dark in an image acquired by cSLO. There may be patients that benefit from FAF imaging using green light, such as patients with small geographic atrophy in the macula or cataracts. The option to select the optimal FAF imaging mode (green or blue) is unique to the ZEISS CLARUS platform. It remains to be determined how capturing a broader range of fluorescence may serve patients and clinicians in differential diagnosis of ocular disease. ZEISS welcomes collaborations with researchers interested in broad spectrum excitation. Please contact your local sales representative or contact us at www.zeiss.com/med/contacts.

References

- ¹ Sparrow JR, Yoon KD, Wu Y, Yamamoto K. Interpretations of fundus autofluorescence from studies of the bisretinoids of the retina. *Invest Ophthalmol Vis Sci.* 2010;51(9):4351–435
- ² Holz FG, Bindewald-Wittich A, Fleckenstein M, Dreyhaupt J, Scholl HP, Schmitz-Valckenberg S. Progression of geographic atrophy and impact of fundus autofluorescence patterns in age-related macular degeneration. *Am J Ophthalmol.* 2007;143(3):463–472.
- ³ Van Schaik HJ, Alkemade C, Swart W, Van Best JA. Autofluorescence of the diabetic and healthy human cornea in vivo at different excitation wavelengths. *Exp Eye Res.* 1999;68(1):1–8.
- ⁴ Sparrow JM, Bron AJ, Brown NA, Neil HA. Autofluorescence of the crystalline lens in early and late onset diabetes. *Br J Ophthalmol.* 1992;76(1):25–31.
- ⁵ Schweitzer D, Hammer M, Schweitzer F, Schenke S (2006) In vivo autofluorescence lifetime imaging at the fundus of the human eye. In: Manns F, Söderberg PG, Ho A (eds) *Ophthalmic technologies XVI*. SPIE, San Jose, pp 613808–1–613808-10.
- ⁶ Schweitzer D, Schenke S, Hammer M, Schweitzer F, Jentsch S, Birckner E, Becker W, Bergmann A (2007) Towards metabolic mapping of the human retina. *Microsc Res Tech.* DOI 10.1002/jemt.20427.
- ⁷ Sharifzadeh M, Bernstein PS, Gellermann W. Nonmydriatic fluorescence-based quantitative imaging of human macular pigment distributions. *J Opt Soc Am A Opt Image Sci Vis.* 2006;23(10):2373– 2387.
- ⁸ Schweitzer D, Jentsch S, Schenke S, et al. Spectral and time-resolved studies on ocular structures. Paper presented at diagnostic optical spectroscopy in biomedicine IV; 2007/06/17, 2007; Munich.
- ⁹ Delori, François C. "Spectrophotometer for noninvasive measurement of intrinsic fluorescence and reflectance of the ocular fundus." *Applied optics* 33, no. 31 (1994): 7439-7452.