

Successful presbyopia correction after hyperopic LASIK using the AT LARA EDoF IOL

By Dr. Claudio Orlich – San José, Costa Rica

CASE HISTORY

A 62-year-old woman presented because of decreased vision. She had undergone hyperopic LASIK 12 years earlier at a different institution, and now she wanted another refractive procedure to regain spectacle independence. Examination showed incipient nuclear sclerosis in both eyes (OU). In the right eye (OD), uncorrected visual acuity (UCVA) was 20/150, best corrected visual acuity (BCVA) was 20/25, and manifest refraction (MR) was +4.25 -1.00 X 30. In the left eye (OS), UCVA was 20/100, BCVA was 20/25, and MR was +4.00 -1.00 x 155 with an addition of +2.25 D. Corneal asphericity measurements showed Q coefficients of -0.64 OD and -0.50 OS, consistent with the hyperopic ablation that causes central steepening and makes the cornea more prolate. The patient was counseled about the possibility of a postoperative refractive surprise because of her history of LASIK. Different IOL options were discussed, including monovision with a spherical IOL and bilateral implantation of the aberration-neutral AT LARA 829MP extended depth of focus (EDoF) IOL. The patient chose the AT LARA IOL.

IOL power was determined using biometry measurements obtained with the IOLMaster 700 (Carl Zeiss Meditec) and the PANACEA IOL calculator (<http://www.panaceaiolandtoriccalculator.com/downloads.html>) based on a target refraction of -0.25 D OU. Surgery was performed with the primary incision made on the steep corneal meridian and paired with a clear corneal incision 180° away to achieve astigmatism correction. Intraoperative aberrometry (ORA, Alcon Laboratories) confirmed the preoperatively selected IOL powers. At 1 month after the second eye surgery, MR was -0.25 -0.50 x 150 OD and -0.25 -0.25 x 45 OS. The patient's UCVA was 20/20 at distance OU and J1 between 40 and 60 cm. Total spherical aberration (SA) was close to 0 in both eyes (-0.054 μ m OD, -0.027 μ m OS).

DISCUSSION

Millions of people worldwide have undergone excimer laser vision correction surgery. Having experienced the advantages of not wearing glasses, these patients are motivated to invest in a refractive procedure when they develop presbyopia or cataract. However, there are challenges for delivering good visual acuity and good visual quality outcomes that are necessary for patient

satisfaction. Avoiding residual refractive error is critical for achieving good visual performance with multifocal IOLs, but accurate IOL power calculation is difficult in eyes with previous refractive surgery. Illustrating this problem, Muftuoglu et al. reported a 42.9% laser enhancement rate after multifocal IOL implantation in a series of 49 eyes with prior myopic LASIK.¹

In addition, some patients have persistent dry eye after LASIK that affects accurate IOL power calculations as well as visual quality. Not surprisingly, dry eye is reported as a leading cause of dissatisfaction after multifocal IOL implantation.² Because of the relationship between higher-order aberrations (HOAs) and quality of vision, changes in corneal HOAs after keratorefractive surgery is another important consideration. As one issue, keratorefractive procedures tend to induce corneal aberrations and multifocality, leading to decreased contrast sensitivity that would be further compromised by multifocal IOL implantation.³

In addition, the effect of prior refractive surgery on spherical aberration (SA) requires particular attention. Because SA reduces retinal image contrast and affects visual quality, especially under mesopic conditions, most modern IOLs feature an aspheric optic that induces negative SA, thereby minimizing total SA by compensating for the slightly positive SA (+0.27 μ m) of the natural cornea.^{4,5} Whereas a keratorefractive surgery for correcting myopia causes corneal SA to become more positive,^{6,7} implanting an aspheric IOL with negative SA in an eye with a history of hyperopic LASIK could worsen the existing negative SA and be expected to have an adverse effect on quality of vision.⁸

Taking the above mentioned factors into account, the AT LARA EDoF IOL can be considered a better choice than a multifocal IOL for pseudophakic correction in patients with a history of corneal refractive surgery. The AT LARA has an aberration-neutral optic with zero SA, provides excellent visual acuity over a wide range of focus from far to near intermediate distances, incorporates patented design and manufacturing technology that reduces visual symptoms, and features chromatic aberration optimization for increased contrast sensitivity. In addition, the EDoF optic of the AT LARA IOL allows for some tolerance to residual refractive errors. We

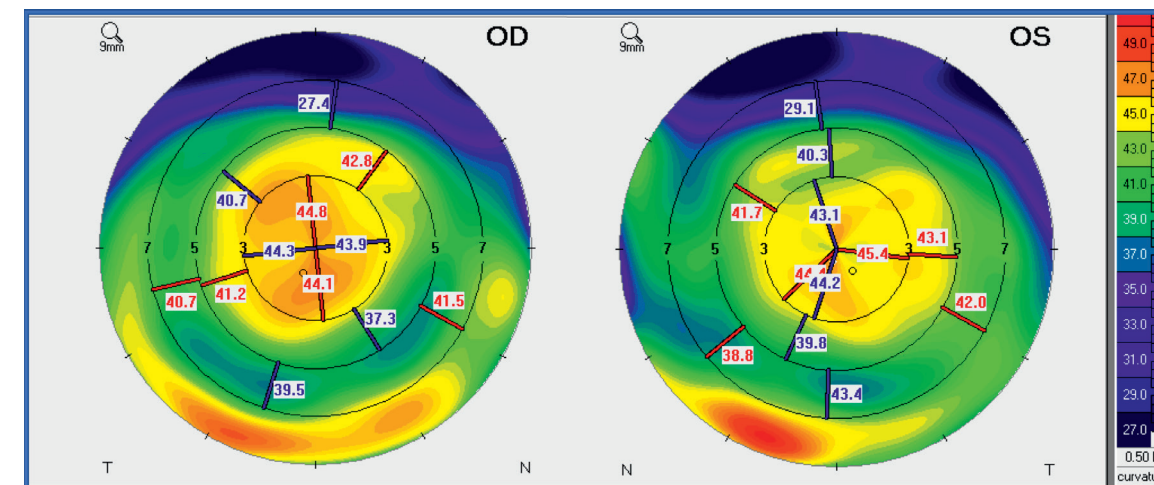


Figure 1. Tangential map from Scheimpflug camera imaging (Pentacam HD, Oculus) shows abnormally prolate corneas as a result of the central steepening generated by hyperopic LASIK.

have implanted the AT LARA EDoF IOL in 14 eyes with a history of hyperopic LASIK. Although our series is small, the outcomes have been excellent. All of the patients achieved spectacle independence for performing daily activities, including reading. A laser enhancement was necessary in only one eye; this rate of just 7.1% compares very favorably with the incidence of 42.9% reported by Muftuoglu et al.¹

We believe that the PANACEA calculator is particularly useful for IOL power calculations in eyes with previous refractive surgery because it uses information on anterior and posterior corneal surface and corneal asphericity. Nevertheless, given the known difficulties of estimating the IOL power in these cases, we aim for a slightly myopic target refraction (-0.25 to -0.50 D; usually the first negative value in the IOL power calculation). The average postoperative refraction achieved in our series of 14 eyes with a history of hyperopic LASIK was -0.3D, and although we found it was associated with very good functional outcomes, other surgeons might prefer choosing a target closer to emmetropia. It should be noted, however, that we do not perform simultaneous bilateral surgery. By operating on just one eye first, we can adjust the refractive target in the second eye depending on the patient's satisfaction with vision after the first eye surgery.

Appropriate preoperative counseling is critical for setting patient expectations. Patients are told that quality distance and intermediate vision is the greatest strength of the AT LARA EDoF IOL and that glasses with a low addition may be needed for reading. They are also informed about the possibility of an inaccurate IOL power calculation with the need for a laser enhancement. We have found, however, that intraoperative aberrometry can be an extremely useful tool for obtaining excellent refractive and functional results in these cases to avoid a second procedure.

CONCLUSION

Achieving consistently excellent results implanting the AT LARA IOL in patients with virgin corneas gave us the confidence to use it in the more challenging group of patients with prior keratorefractive surgery. The SA-neutral optic of the AT LARA makes it particularly well-suited for use in patients with a history of a hyperopic refractive procedure, but the AT LARA IOL has many advantages that make it an excellent option in patients with prior myopic LASIK. In all cases of virgin and operated corneas, careful candidate selection and preoperative counseling are critical for achieving success and patient satisfaction postoperatively.

References

1. Muftuoglu O, Dao L, Mootha VV, et al. Apodized diffractive intraocular lens implantation after laser in situ keratomileusis with or without subsequent excimer laser enhancement. *J Cataract Refract Surg.* 2010;36(11):1815-1821.
2. Gibbons A, Ali TK, Waren DP, Donaldson KE. Causes and correction of dissatisfaction after implantation of presbyopia-correcting intraocular lenses. *Clin Ophthalmol.* 2016;10:1965-1970.
3. Braga-Mele R, Chang D, Dewey S, et al; ASCRS Cataract Clinical Committee. Multifocal intraocular lenses: relative indications and contraindications for implantation. *J Cataract Refract Surg.* 2014;40(2):313-322.
4. Oshika T, Tokunaga T, Samejima T, et al. Influence of pupil diameter on the relation between ocular higher-order aberration and contrast sensitivity after laser in situ keratomileusis. *Invest Ophthalmol Vis Sci.* 2006;47(4):1334-1338.
5. Holladay JT, Piers PA, Koranyi G, van der Mooren M, Norrby NE. A new intraocular lens design to reduce spherical aberration of pseudophakic eyes. *J Refract Surg.* 2002;18(6):683-691.
6. Chen CC, Izadshenas A, Rana MA, Azar DT. Corneal asphericity after hyperopic laser in situ keratomileusis. *J Cataract Refract Surg.* 2002;28(9):1539-1545.
7. Wang L, Koch DD. Anterior corneal optical aberrations induced by laser in situ keratomileusis for hyperopia. *J Cataract Refract Surg.* 2003;29(9):1702-1708.
8. Orlich C. Understanding spherical aberration. *Eyeworld.* January 2018.

Dr. Claudio Orlich, Dr. Orlich is the Medical Director of Clínica 20/20, San José, Costa Rica, where he specializes in corneal and refractive surgery. He is a consultant to Carl Zeiss Meditec.

